

Thermal imaging in skin trauma evaluation: observations by CAT S60 mobile phone

Jarmo Alametsä¹, Markku Oikarainen¹, Jarmo Perttunen¹, Jari Viik², Annikki Vaalasti³

¹Tampere University of Applied Sciences, Tampere, Finland; ²BioMediTech Institute and Faculty of Biomedical Science and Engineering, Tampere University of Technology, Tampere, Finland; ³Department of Dermatology, Tampere University Hospital, Tampere, Finland

Jarmo Alametsä, Tampere University of Applied Sciences, FI-33520 Tampere, FINLAND. Email: jarmo.alametsa@health.tamk.fi

Abstract

The purpose of this study was to evaluate the usability of a mobile phone with inbuilt thermal camera in wound imaging for medical purposes. Thermal imaging could help in evaluating wound healing and in assisting doctors in diagnose making. By using CAT S60 smart phone with an inbuilt Flir thermal camera, thermal pictures from skin wounds and lower limbs were taken from six people in order to find out if thermal imaging could help the treatment and diagnosis of a patient. Thermal images were taken in order to find and visualize temperature changes (being normally invisible) in skin damage areas including deep skin damages especially from limbs and extremities.

By using thermal imaging the beginning of treatment could be hastened and the monitoring of the state of a patient would be more efficient thus improving the prognosis of a patient. The thermal pictures taken from skin damages suggest that thermal imaging with CAT S60 smart phone can be used to improve nursing methods and may also help in diagnosis. Non-invasive thermal imaging may be a valuable asset and for its part hasten the beginning of treatment. The resolution and properties of CAT S60 smart phone was sufficient to detect skin damage temperature changes. This may suggest the usage of the CAT S60 smart in hospital, emergency ward and in home care services.

Keywords: thermal imaging, wound infection, diabetes

Introduction

New ways to study wounds and underlying tissue metabolism non-invasively are needed. Thermal imaging reveals the body surface temperature by measuring the emitted infrared thermal radiation forming a digital image of the measured temperatures. Body surface temperature and its infrared radiation correlates to blood flow volume to the skin and the temperature of limbs depend on the peripheral blood flow volume [1].

The purpose of the blood circulation along with the transportation of oxygen, waste products and nutrients is to convey heat thus acting as a part of thermoregulation.

The relationship between body surface temperature and disease has been well known for physicians. In 400 BC, Hippocrates wrote aptly, 'In whatever part of the body excess of heat or cold is felt, the disease is there to be discovered'. Therefore changed body surface

temperature may be an indication of infection, deep inflammation or repetitive trauma [2,3]. Skin temperature correlates directly to the physiologic processes of circulation, to the microcirculation and underlying metabolic activity. Reperfusion injury is due to the return of blood supply to tissue after an ischemic event (due to oxidative damage). Altered underlying tissue circulation, microperfusion and metabolic activity appear as changes in skin temperature. Thermal energy seen on body surface reflects the presence or absence of perfusion of the dermal and subcutaneous tissues [4]. Thermal imaging has been used on dermatological diseases, with diabetes mellitus patients having foot ulceration, inflammatory state studies [5,3] and to diagnose arthritis [1]. It has been used in the screening of fever, to detect vascular disorders from diabetic subjects, in arterial blood pressure monitoring and in the diagnosis of rheumatic diseases [6]. It can reveal temperature variations as a first symptom before the onset of harmful tissue changes and problems in blood circulation [5].

In medical practice, the inspection of a wound is mainly based on the visual evaluation of the physician. There are no standardized instruments to evaluate the moisture of a wound, the swelling of the surrounding healthy tissue or colour or the amount of the granulation tissue in the basis of the wound. The evaluation of the appearance of the wound is based on visual perception [7], and thus is prone to errors. The traditional clinical techniques fail to identify changes in the integrity of the skin until ulcerations appear [3]. Risk factors of diabetic foot (peripheral neuropathy and vascular disease) induce superficial temperature fluctuations that can be detected also with infrared thermometry. These temperature fluctuations in the plantar foot areas due to diabetic foot complications have been reported in many studies [3]. Infrared thermometry has an advantage over the traditional assessment tools (monofilament and vibration sensation test) due to its non-contacting operation. No contact and no pressure on the skin that may affect the temperature readings and contribute to the spreading of infection through the measuring apparatus. It also makes possible to measure the temperature distribution of the whole body irrespective of the shapes of skin surface. Pictures can be

taken also by non-clinicians thus widening its usability [3]. In wound healing thermal imaging may give systematic extra information about the amount of tissue, the edges of a wound, the level of infection and moisture of the wound. This extra information accelerates the process of wound evaluation and the beginning of proper healing methods.

The objective of this preliminary study was to explore whether CAT S60 smart phone can show abnormal temperature patterns in pictures taken from skin trauma patients. The pictures were taken in order to find out, if thermal imaging for its part might help in skin wound and deeper tissue damage evaluation via radiated heat giving a hint of the sufficient amount of blood circulation in limbs.

Materials and methods

CAT S60 smart phone with an inbuilt Flir thermal camera with MSX technology was used to obtain thermal pictures from six voluntary people on condition revealing the state of local circulation seen as radiated heat from the different part of the body. CAT S60 smart phone has a dynamic temperature range of -20 – +120 C° and the thermal imaging is up to 30 meters. Thermal image is embedded in normal 13MP picture.

Flir thermal pictures with CAT S60 smart phone [8] (combined with regular images) were taken in Tampere University Hospital (during fall 2017) (Figures 1–6). There were six cases in the study. Some of them were in the outpatient reception for inspection and others were in ward to get medical treatment. The pictures were taken in freehand having a close distance from the limb. In thermal pictures the skin areas, whose the temperature value differed from 30 C° were examined.

Results

The obtained thermal images with CAT S60 smart phone proposed, that it can visualize abnormal temperature patterns about skin and deeper tissue lesions in the form of emitted heat reflecting the amount and the

state of blood circulation. In thermal pictures, temperature values from the trauma and healthy skin region has been labelled in order to point out temperature values between these regions. No further medical details were available from voluntary people.

In Figure 1, the temperature of the skin lesion area is lower when compared with other skin areas. In Figure 2

temperatures over 30 C° were observed, both in skin lesion area and in other skin areas. In Figure 3, the sole area has temperatures over 30 C°. In Figure 4, badly injured area has temperatures below 30 C°. In Figure 5A, the temperature of the visually intact skin area has values over and below 30 C° but in Figure 5B over 30 C°. In Figure 6A, the temperature of the sole stays significantly lower than 30 C°, but in Figure 6B closer to 30 C°.

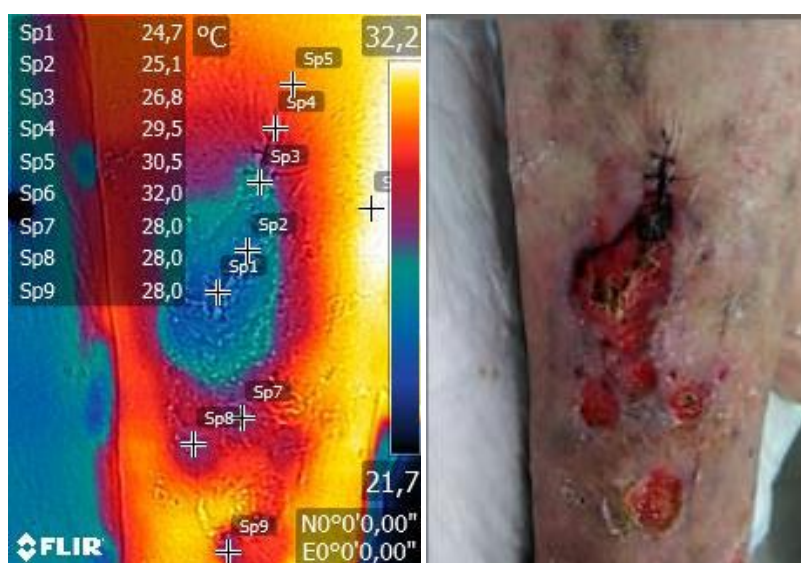


Figure 1. Thermal images from the right lower leg with ulceration (case 1). In the skin lesion area, the temperature is lower when compared with other skin areas. The normal skin temperature (body heat radiation) is about 30 C°. Temperature colour scale is situated on the right in the thermal picture.

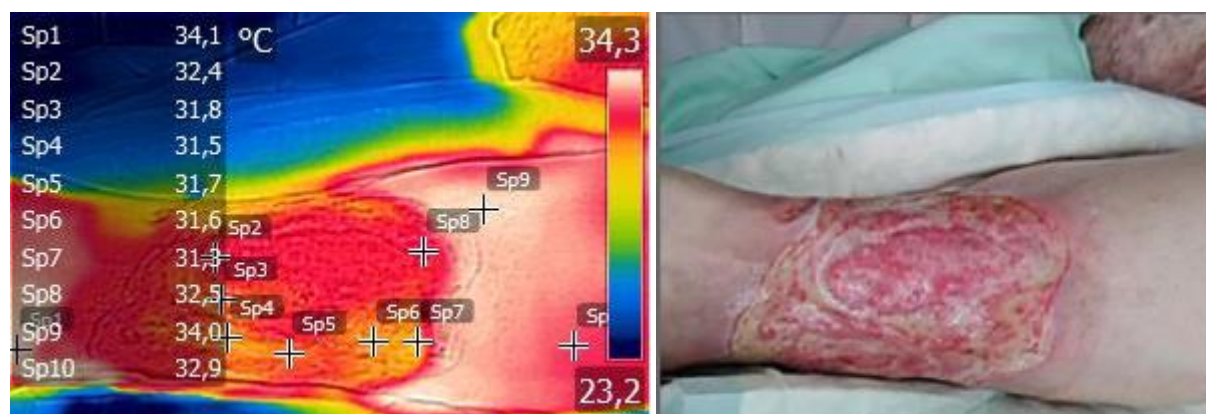


Figure 2. Thermal image from the left lower leg with a large ulcer from case 2. In the skin lesion area, the temperature is lower when compared with other skin areas. All the temperatures are over 30 C°.

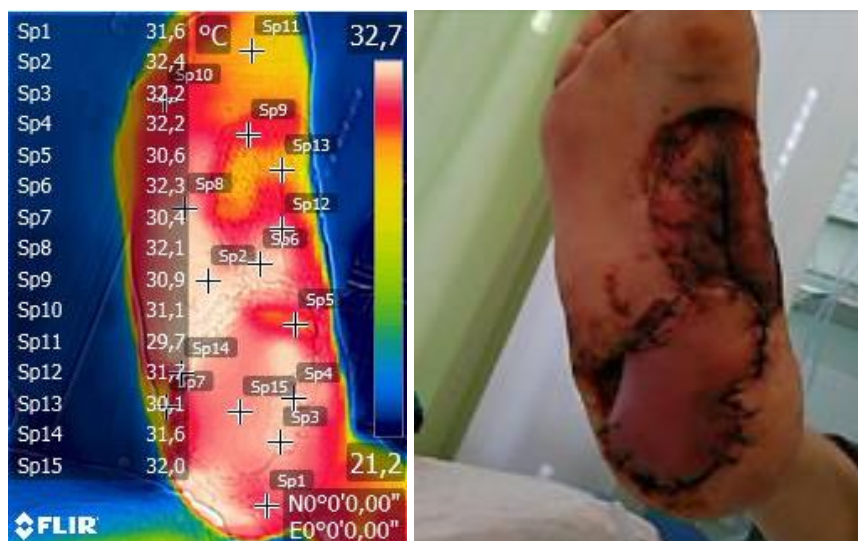

Figure 3. Thermal image from the right sole from case 3 (microvascular reconstruction of diabetic foot ulcer). Thermal trace in the transplant area (Sp3, Sp15) shows adequate blood circulation seen as temperatures 32 °C or over. The colour of the transplant in the normal picture seems viable. Lower temperatures are seen in the area without transplant (Sp5, Sp13).

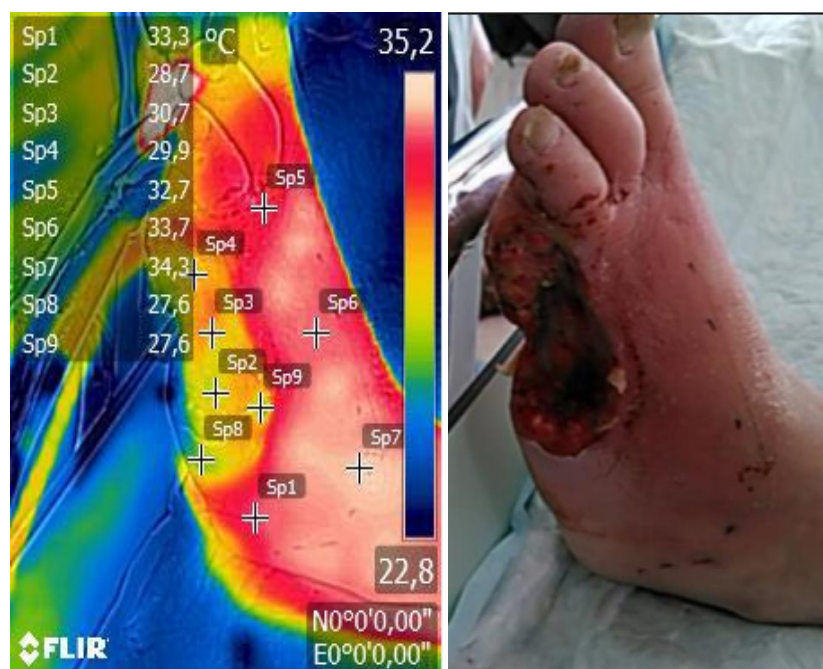

Figure 4. Thermal image from the left foot from case 4 (surgically debrided diabetic foot ulcer). The instep area has higher temperature values (Sp1, Sp5, Sp6, Sp7) when compared with injured area (Sp2, Sp3, Sp4). Green colour in thermal image (Sp8, Sp9) and faded colour in normal picture may indicate presence of coat or dried skin in the border of the lesion.

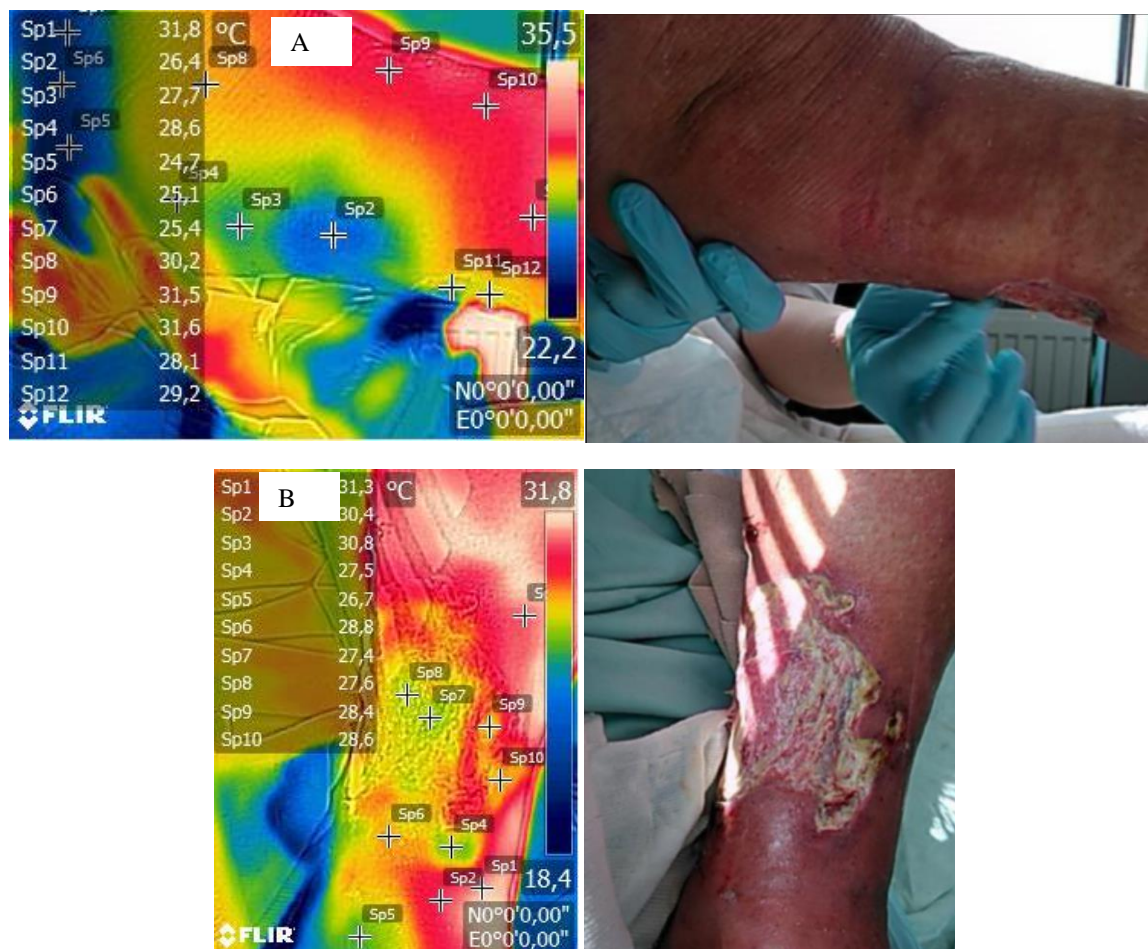


Figure 5. A) Thermal image from the left foot from case 5. The sole on the left is colder (Sp5, Sp6, Sp7) when compared with other areas (Sp1, Sp9, Sp10) indicating inadequate blood circulation in the sole area. Colder areas (Sp2, Sp3) also exist. In the lesion area, smaller temperatures are seen when compared with (Sp1, Sp9, Sp10). **B)** Thermal image from the left foot from case 5. The presence of possible coat is seen as lighter areas in normal picture. Normal temperatures are seen in areas (Sp1 – Sp3). Lower temperatures are seen in skin lesion areas (Sp4 – Sp10).

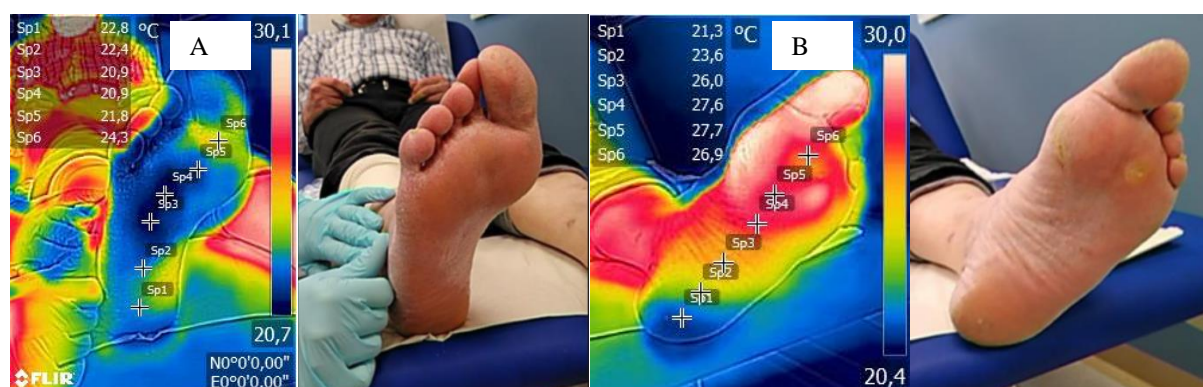

Figure 6. Thermal images (right and left foot plantar temperature distribution) from case 6 (diabetic patient). **A)** On the right foot sole low skin temperatures are seen. **B)** On the left foot heel low skin temperature is seen indicating inadequate blood circulation. Having less visible in normal picture the thermal picture reveals instantly non-invasively impaired sole circulation.

Discussion

In this preliminary study skin lesions and their thermal traces were studied by utilizing CAT S60 smart phone with inbuilt Flir thermal camera to obtain complementary patient information for the aid for diagnosis and treatment. Our aim was to find out, if thermal imaging gives further information about skin lesions compared with regular pictures. We did not study the wound healing process but mainly to propose a new way to evaluate the condition of the wound. The purpose is to join thermal pictures to the chain of perception as a part of quantitative wound evaluation. The resulted images propose that the properties of practical CAT S60 smart phone seem to be sufficient for chronic wound quantitative temperature evaluation.

When in regular picture the lesion or local area of the skin is well presented, it does not show the state of circulation. As thermal image is embedded in the normal picture, the resulting image may give extra information in the form of colours reflecting the amount of emitted heat from the lesion area under study. Inadequate blood circulation in the sole has earlier studied with strip like thermometers, which changed their colour according to the skin temperature. As they needed contact with the skin (and difficulties of measuring the temperature at many points on foot), they were not as practical as non-invasive thermal imaging.

Normally arterial blood flow is symmetrical in proximal and distal arterial circulation. Diabetic ischemic limbs may lose their normal symmetrical arterial blood flow due to asymmetrical plaque and blockade formation increasing impedance in the arterial system. Increased artery impedance may lead to measurable temperature differences in distal circulation. Temperature variations may be seen in limb ischemia in lower regional, having local and side-to-side variability. Unequal vascular supplies may be found by measuring the proximal and distal locations of wound temperatures. Having an intact skin with local temperature increase may refer to local inflammation. Ulcer existence may indicate infection [9]. Signs of deep infection or inflammation can be observed via infrared thermometry emitted by the skin [9]. Increased local temperature (Fig. 2) may be due to

repetitive trauma (inflammation and tissue enzymatic autolysis). This may be the case with diabetic patients having foot ulceration which precedes lower limb amputation in 85% of diabetic people [9]. About 6% of the diabetic patients are at risk of developing peripheral neuropathy. It may lead to insensitive and deformed foot with limited joint movement. This induces large pressure on certain regions forming callus (dense skin). Increased pressure loading causes bleeding into the skin and eventually ulcerations [3].

The indirect signs of high-risk foot include the occurrence of callus (due to increased local pressure) or hemorrhagic blister (due to shear and blister) and previous amputations (digit or part of the foot). Non-contact infrared thermometry in skin surface temperature measurement with diabetic patients with associated neuropathy has been valued as an effective diagnostic tool also in patient home monitoring [9]. The radiating temperature from the skin reflects well local blood circulation. If it is inadequate, the insufficient tissue circulation activates compensatory mechanisms in the body. In the form of skin lesions in the limbs or extremities, inadequate blood circulation may lead to improper limb operation or even extremity necrosis.

When relative temperature maximum in wound infection and inflammation was compared with normal control subjects with similar anatomical wound locations, an elevation of temperature of +4 C° to 5 C° between the wound and healthy skin was detected. Subjects having the clinical signs of inflammation had relative thermal changes from +1.2 C° to 2.2 C°. With normal control subjects without the diagnosis of infection or signs of inflammation had relative +1.1 C° to 1.2 C° temperature differences. Wounds having differential temperature increase of +1 C° to +3 C° apparently indicate not an infection but a healthy post infection healing inflammatory state [10]. When contralateral limb or body structure was studied with infrared skin thermometry, a difference of 3 C° or greater suggested the presence of wound inflammation/infection [11]. Subjects having risk at diabetes had significantly higher mean foot temperature (30.2 ± 1.3 C°) when compared with the normal cases (26.8 ± 1.8 C°) [6].

The infrared thermography camera technology has advanced in terms of resolution and response time and has now widely used for medical purposes. Rapid capturing of picture elements (pixels) is now possible and these individual pixels at the respective points in the picture represent the temperature. Forming image from the pixels reflect the surface temperature distribution [3]. Thermal imaging cameras (FLIR devices) have great potential in austere and pre-hospital environments. The benefit of the infrared thermography is, that it offers the real time temperature visualization on the body surface, is non-invasive, cheap, fast, non-contact (does not effect the surface temperature) and easy to use thus being a clear advantage in health care operations. FLIR devices have been used to identify perfusion in perforator vessels (and imaging of extremity perfusion), assessment of respiratory rate and inflammation evaluation in diabetic foot and pressure ulcers [12]. In nursing the thermal borders from limbs and from the whole body is usually obtained with thermometers needing contact with the skin. Thermal borders can be found also with a hand touching the skin. With a smart phone having internal thermal camera thermal borders and the differences in limbs can be easily seen from a single picture [5].

Thermal imaging (Figs. 1, 2) may be used to study skin wounds which are situated in the superficial skin layers [5]. The amount of blood flow in the skin of the transplant seen as radiated heat may be evaluated when compared with surrounding tissue heat radiation (Fig. 3). Also the progressive inflammation due to increased blood flow might be more visible observed via thermal pictures. Thermal image may give a hint of the areas of sufficient blood flow (Fig. 4) when tissue removal is actual. It may also help in evaluating the amount of circulation in deeper tissue when compared with surrounding tissue (Fig. 5). Bedsores due to long lasting immobilization, work limitation in the muscles and respectively, a disturbance in the circulation of blood of the patient could possibly be found with a thermal camera [5]. Very promising usage target might be the evaluation (Fig. 6) of the amount of sufficient sole circulation. Lower sole temperature may indicate inadequate amount of circulation and incoming problems.

The Flir Android application is very easy to use not needing any special knowledge. The Flir software has a property to show both normal and thermal image in the same picture one upon another allowing separating pictures with a sweeping of a finger. The ability to figure the skin thermal differences embedded in the normal picture makes possible to see the temperatures of skin lesions. Obtained thermal pictures suggest that it is possible to observe temperature differences due to decreased blood circulation. Further studies, where the data from thermal camera correlates with other blood vessel imaging methods (toe pressure measurement, ankle-brachial index (ABI), etc.) are needed. If the correlation is adequate, the thermal camera could be used in screening for example in health centres and in home care services in order to detect decreases in arterial flow in time.

The CAT S60 with Flir software is relatively easy to integrate the taking of thermal pictures into the daily routines in health care. Thermal imaging is suitable for mass screening revealing the state of the vasculature system non-invasively. The present preliminary study suggests that thermal imaging with CAT S60 might help to evaluate skin lesion severity and may help in follow-up intention studies.

References

- [1] Deng F, Tang Q, Zheng Y, Zeng G, Zhong N. Infrared thermal imaging as a novel evaluation method for deep vein thrombosis in lower limbs. *Medical Physics* 2012; 39(12):7224-31. <https://doi.org/10.1118/1.4764485>
- [2] Mufti A, Coutts P, Sibbald RG. Validation of commercially available infrared thermometers for measuring skin surface temperature associated with deep and surrounding wound infection. *Advances in skin & Wound care* 2015;28(1):11-6. <https://doi.org/10.1097/01.ASW.0000459039.81701.b2>
- [3] Adam M, Nq EYK, Tan JH, Henq ML, Tong JWK, Acharya UR. Computer aided diagnosis of diabetic foot using infrared thermography: A review. *Computers in Biology and Medicine* 2017;91:326-336. <https://doi.org/10.1016/j.combiomed.2017.10.030>

- [4] Langemo D, Spahn JG. A reliability study using a long-wave infrared thermography device to identify relative tissue temperature variations of the body surface and underlying tissue. *Advances in skin & Wound care* 2017;30(3):109-119. <https://doi.org/10.1097/01.ASW.0000511535.31486.bb>
- [5] Cholewka A, Stanek A, Klimas A, Sieron A, Drzazga Z. Thermal imaging application in chronic venous disease. Pilot study. *Journal of Thermal Analysis and Calorimetry* 2014;115(2):1609-1618. <https://doi.org/10.1007/s10973-013-3356-0>
- [6] Lahiri BB, Bagavathiappan S, Jayakumar T, Philip J. Medical applications of infrared thermography: A review. *Infrared Physics & Technology* 2012;55:221-235. <https://doi.org/10.1016/j.infrared.2012.03.007>
- [7] Koljonen V, Väänänen U, Isoherranen K. Mikä on lääkärin rooli haavanhoidossa. *Lääkärilehti* 2017;72(8):484-485.
- [8] Cat S60 Smartphone User manual. Caterpillar; 2016 [Accessed 8.4.2018]. Available from: <https://www.catphones.com/wp/wp-content/uploads/sites/2/manuals/s60-user-manual.pdf>
- [9] Sibbald RG, Mufti A, Armstrong DG. Infrared skin thermometry: An underutilized cost-effective tool for routine wound care practice and patient high-risk diabetic foot self-monitoring. *Advances in skin & Wound care* 2015;28(1):37-44. <https://doi.org/10.1097/01.ASW.0000458991.58947.6b>
- [10] Chanmuqam A, Langemo D, Thomason K, Haan J, Altenburger EA, Tippett A, et al. Relative temperature maximum in wound infection and inflammation as compared with a control subject using long-wave infrared thermography. *Advances in skin & Wound care* 2017;30(9):406-414. <https://doi.org/10.1097/01.ASW.0000522161.13573.62>
- [11] Mufti A, Somayaji R, Coutts P, Sibbald RG. Infrared skin thermometry: Validating and comparing techniques to detect periwound skin infection. *Advances in skin & Wound care* 2018;31(1):607-611. <https://doi.org/10.1097/01.ASW.0000527352.75716.70>
- [12] Barron MR, Kuckelman JP, Mccellan JM, Decrikson MJ, Phillips CJ, Marko ST, et al. Smartphone-based mobile thermal imaging technology to assess limb perfusion and tourniquet effectiveness under normal and blackout conditions. *Journal of Trauma and Acute Care Surgery* 2017;83(6):1129-1135. <https://doi.org/10.1097/TA.0000000000001639>